



ELSEVIER

Journal of the Neurological Sciences xx (2007) xxx–xxx

 Journal of the  
**Neurological  
 Sciences**

www.elsevier.com/locate/jns

## Stem cell treatment in Amyotrophic Lateral Sclerosis

Letizia Mazzini<sup>a,\*</sup>, Katia Mareschi<sup>b</sup>, Ivana Ferrero<sup>b</sup>, Elena Vassallo<sup>b</sup>, Giuseppe Oliveri<sup>c</sup>,  
 Nicola Nasuelli<sup>a</sup>, Gaia Donata Oggioni<sup>a</sup>, Lucia Testa<sup>a</sup>, Franca Fagioli<sup>b</sup>

<sup>a</sup> Department of Neurology, “Eastern Piedmont” University of Novara, Novara, Italy

<sup>b</sup> Department of Pediatrics, Regina Margherita Children’s Hospital, University of Turin, Turin, Italy

<sup>c</sup> Department of Neurosurgery, Azienda Ospedaliera Universitaria Senese, Siena, Italy

Received 9 February 2007; received in revised form 8 April 2007

### Abstract

Amyotrophic Lateral Sclerosis is a progressive fatal neurodegenerative disease that targets motor neurons. Its origin is unknown but a main role of reactive astrogliosis and microglia activation in the pathogenesis has been recently demonstrated. Surrounding neurons with healthy adjoining cells completely stops motor neuron death in some cases. Hence stem cell transplantation might represent a promising therapeutic strategy. In this study MSCs were isolated from bone marrow of 9 patients with definite ALS. Growth kinetics, immunophenotype, telomere length and karyotype were evaluated during *in vitro* expansion. No significant differences between donors or patients were observed. The patients received intraspinal injections of autologous MSCs at the thoracic level and monitored for 4 years. No significant acute or late side effects were evidenced. No modification of the spinal cord volume or other signs of abnormal cell proliferation were observed. Four patients show a significant slowing down of the linear decline of the forced vital capacity and of the ALS-FRS score. Our results seem to demonstrate that MSCs represent a good chance for stem cell cell-based therapy in ALS and that intraspinal injection of MSCs is safe also in the long term. A new phase 1 study is carried out to verify these data in a larger number of patients.

© 2007 Elsevier B.V. All rights reserved.

**Keywords:** Amyotrophic Lateral Sclerosis; Mesenchymal stem cells; Bone marrow; Transplantation; Spinal cord; Motor neuron diseases

### 1. Introduction

ALS is a devastating incurable neurodegenerative disease that targets motor neurons. It manifests as a linear decline in muscular function which eventually leads to paralysis, speech deficits and dysphagia. Within 2 to 5 years of clinical onset death, due to respiratory failure, occurs. [1] The vast majority of MND cases are sporadic; the aetiology of which is unknown and the pathogenesis is incompletely understood. Great interest has been focused on inflammatory processes and microglia activation. Microglia are subcomponents of the immune system that play a major role in advancing or limiting the disease [2].

Recent data have implicated the microenvironment of the motor neuron, rather than the motor neuron itself, as a primary target of the pathophysiology [3]. Some support for this hypothesis is provided by rodent models of ALS where focally delivered BM mononuclear cells modify the clinical phenotype [4,5]. In some cases, having normal cells completely stops motor neuron death [5]. In addition to immunomodulatory activity [5,6], several known properties of these cells, including production of neurotrophic factors [7] and stimulation of endogenous repair [8], may also be of relevance to their effect. Taken together these findings support a clinical translation trial of focally delivered cell therapies in human MND [6].

Mesenchymal stem cells from bone marrow are widely used in many human diseases because their potential to replicate as undifferentiated forms and to differentiate to multiple lineages [9] moreover their safety has been largely demonstrated [10]. Evidences of their differentiation in

\* Corresponding author. Department of Neurology, “Eastern Piedmont” University, Azienda Ospedaliera “Maggiore della Carità” Corso Mazzini 18, 28100 Novara, Italy. Tel.: +39 0321 3733834; fax: +39 0321 3733298.

E-mail address: mazzini.l@libero.it (L. Mazzini).

neural cells and glia have been reported by some authors both *in vitro* [11,12] and *in vivo* [13] but not confirmed by others [14,15]. Recently our laboratory studied human mesenchymal stem cells (hMSCs) in different cell culture conditions in both those already in use [11,12] and in new ones, from morphological, immunochemical, gene expression, and physiological points of view. In our new culture condition consisting in a neural progenitor maintenance medium (NPM), containing growth factors such as hFGF, hEGF, NSF-1, hMSCs acquired new morphological characteristics, neural markers, and electrophysiological properties, which are suggestive of neural differentiation [16]. MSCs had shown the ability to promote neural recovery in different experimental models of neurological diseases [17,18]. MSCs selectively target injured tissue and promote functional recovery by different mechanisms such as the production of neurotrophic factors [19,20], the stimulation of angiogenesis and synaptogenesis [20], cell fusion [21]. The human mesenchymal stem cells when transplanted into the spinal cord of SOD 1 mice survive, proliferate and migrate and determine a significant reduction of the reactive gliosis and microglia activation resulting in the improvement of the behavioral tests [22]. This might lead to a clinical use of hMSCs in neural degenerative diseases. In this paper we present the preliminary results concerning the potential use of MSCs as therapeutic agents in ALS. Intraspinal delivery of the cells was needed because the impediment of stem cells to cross the blood brain barrier which is intact in ALS such as in other neurodegenerative diseases [23].

## 2. Methods

Inclusion criteria were: diagnosis of definite ALS according to the El Escorial criteria [24], mild to severe functional impairment at the spinal level, no or mild signs of bulbar involvement, no signs of respiratory failure, normal polysomnography, good understanding of the experimental protocol and normal psychological profile defined by Minnesota Multiphasic Personality Inventory (MMPI) test [25]. Patients were excluded if they had evidence of any concurrent illness or were receiving any medications that could affect bone. Standard therapies were used throughout the study.

The patients, in order to estimate the disease progression rate before transplantation, had a six months period of natural history observation. They were monitored every three months by clinical evaluation which included ALS-FRS [26], Norris score [27] and Forced Vital Capacity. These measures show a linear progressive decline during the course of the disease and are commonly used in clinical trials [28,29]. The Bulbar functions were also scored on a scale from 3 (normal) to 0 (markedly impaired) for speech and from 4 (normal) to 0 (markedly impaired) for eating, the maximum Bulbar score was 7 [30]. After MSC implantation the patients were monitored for at least 48 months by the same clinical assessment performed by the same examiners. Patients who became unable to attend the monitoring center were contacted by telephone: ALS-FRS

scale [31] and an unstructured interview were delivered. Neuroradiological assessment consisted of MRI of brain and spinal cord before and after Gadolinium DTA infusion. It was performed before transplantation and 1 week, 3, 6, 12, 36, 48 months after surgery. Somatosensory Evoked Potentials (SEPs) were also recorded before and after surgery. All patients were also examined at each visit by a clinical health psychologist and the following questionnaires were provided: Profile of Mood State (POEMS), [32] The SEIQoL-DW [33].

## 3. Experimental procedures

### 3.1. Bone marrow

Bone marrow was collected from the iliac crest in epidural anesthesia according to the standard procedure [34].

### 3.2. Isolation of MSCs

BM cells were centrifuged at  $900 \times g$  for 15 min to discard the anticoagulant medium and then layered on a Percoll (Sigma Aldrich, St. Louis, MO, USA) gradient (density: 1.073 g/ml) and centrifuged at  $1100 \times g$  for 30 min, according to a previously reported method [35]. The cells in the interphase were recuperated, washed twice with PBS1X ( $200 \times g$  for 10 min) and seeded at a density of  $800,000/\text{cm}^2$  in MSC Medium (Cambrex Bioscience, Versviers, Belgium) containing 10% of Fetal Bovine Serum (FBS) and maintained at  $37^\circ\text{C}$  with an atmosphere of 5%  $\text{CO}_2$ . After 3 days, the nonadherent cells were removed and refeed every 3 to 4 days. In order to expand the isolated cells, the adhered monolayer was detached with trypsin/EDTA (Cambrex Bioscience, Versviers, Belgium) for 5 min at  $37^\circ\text{C}$ , after 15 days for the first passage and every 7 days for successive passages. During *in vitro* passaging the cells were seeded at a density of  $8000/\text{cm}^2$  and expanded for 2 to 3 passages.

### 3.3. Cellular expansion analysis of MSCs

Cellular expansion growth rate of donor and patient MSCs was evaluated by cell count in a Burkner Chamber at each passage and expressed in terms of population doubling (PD) as performed in the Stenderup et al. studies [36]. The immunophenotype analysis of adherent cells was performed, at each passage, by flow cytometry analysis.  $2$  to  $5 \times 10^5$  cells were stained for 20 min with anti CD45 fluorescein isothiocyanate (FITC), CD14 phycoerythrin (PE), CD90FITC, CD106PE, CD29FITC, CD44PE, CD105PE, CD166FITC (Becton Dickinson, San Jose, CA, USA) and  $0.5 \mu\text{g}/\text{ml}$  of Propidium Iodide (Sigma) for the viability. Labeled cells were thoroughly washed with PBS 1X and were analyzed on a Epics XL cytometer (Beckman Coulter, CA, USA) with the XL2 software program. The percentage of positive cells was calculated using the cells stained with Ig FITC/PE as a negative control. At each passage MSCs were also analyzed for viability, sterility, mycoplasma detection, cytogenetic and telomeric analysis according to the guidelines of the Italian Institute of Health and showed by Mareschi et al [37].

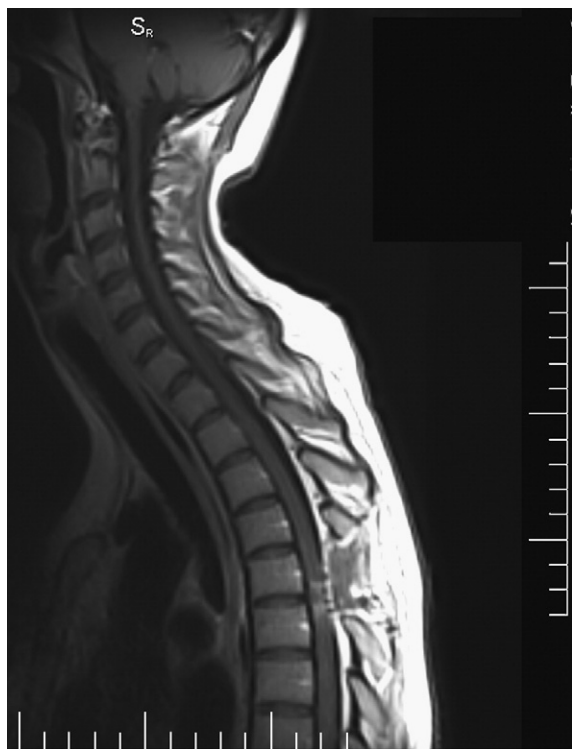

Fig. 1. Sagittal MR imaging of a patient taken one week after MSCs implantation.

#### 3.4. Implantation of autologous MSCs in ALS patients

Before implantation the cells were maintained for at least 3 h in basal MSC Medium (Cambrex) without serum, detached and washed 3 times with PBS 1X containing 1% human albumin and 1 time with autologous cerebrospinal fluid. The cells were suspended in about 1 ml of autologous cerebrospinal fluid and directly transplanted into the surgically-exposed spinal cord at different thoracic levels. A laminectomy was performed and the dura was opened along the median line under microscopical vision. After a median mielotomy, the cells were injected 1 mm apart in the most central part of the spinal cord by means of the ago cannula (18 ga) syringe previously mounted in an injection system with a micrometric pump injector supported by a table-fixed arm. In general injections were made in a pattern of three rows 3 mm apart. At the end of the procedure the dura was closed in a tight-water fraction. The procedure was performed in general anesthesia using short-acting drugs.

## 4. Results

#### 4.1. Patients

Seven patients (4 Females and 3 Males) were consecutively enrolled from October 2001 to May 2002 to receive intraspinal injections of autologous MSCs. Two patients (1M and 1F) were treated for compassionate use in the same period, after approval by the local ethic committee. The study was approved by the Ethical Committee of the Piedmont Region. They gave

their informed consent to participate in the study and underwent bone marrow collection. The median ages of patients were 44 years (21–75 years). The median duration of the disease from diagnosis was 24 months (6–96 months).

#### 4.2. Bone marrow collection and MSCs expansion

No side effects (including pain at the posterior iliac crest lasting 48 h and infection episodes) were recorded after bone marrow collection. The cells isolated from these patients were MSCs showing the specific features defined by the International Society for Cellular Therapy guide lines [38]. In fact, they were adherent cells positive for CD90, CD106, CD29, CD44, CD105, CD166 marker, negative for the hemopoietic markers such as CD45 and CD14 and able to differentiate in osteoblasts, chondroblasts and adipocytes (data not shown). The analysis of MSCs isolated from patients showed no statistically significant difference when compared to those obtained in the healthy donors because extensive *in vitro* expansion of patient MSCs does not involve any functional modification of the cells, including chromosomal alterations or cellular senescence [39].

#### 4.3. Surgical procedure

A mean of  $57 \times 10^6$  cells (range:  $7.0 \times 10^6$ – $152 \times 10^6$ ) was implanted. There were no anesthetic complications. No patients manifested severe adverse events defined as respiratory failure, death and neurological symptoms which persisted

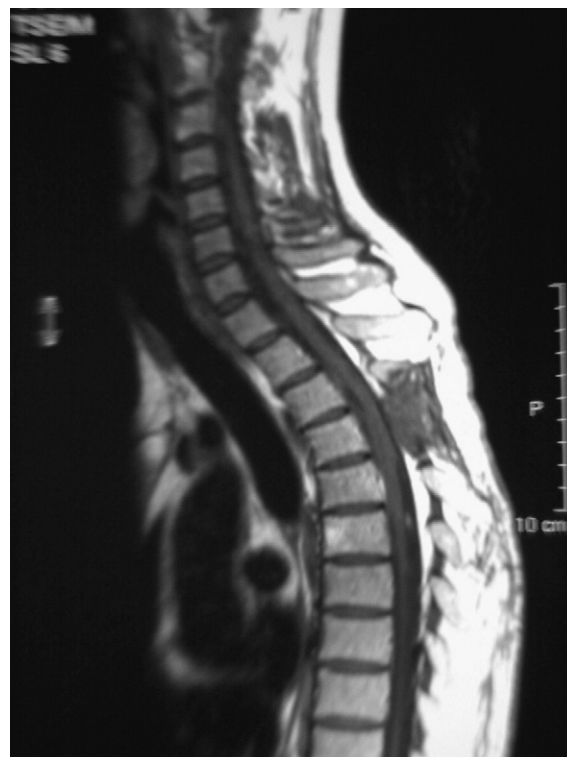

Fig. 2. Sagittal MR imaging of a patient taken 4 years after MSCs implantation.

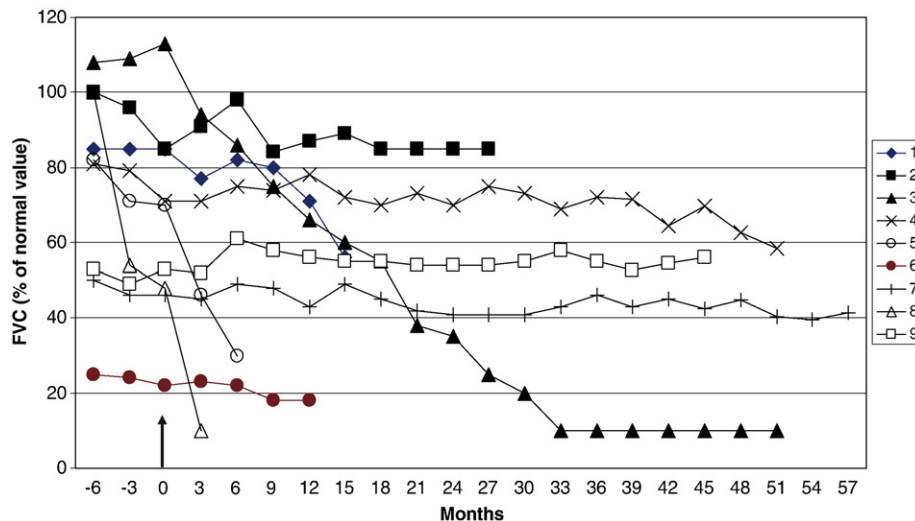


Fig. 3. Clinical long term follow-up. Changes of the forced vital capacity in the 6-month period of natural history observation and after transplantation. The arrow indicates the time of MSCs transplantation.

for more than 6 weeks after MSC implantation. Minor adverse events were intercostal pain irradiation (4 patients) in the site of surgery which was reversible after a mean period of 3 days and leg sensory disesthesia (6 patients) which improved after a mean period of 4 weeks. No patients manifested bladder and/or bowel dysfunction or leg motor deficit. Fig. 1 shows MRI images performed 1 week after surgery. The sites of MSCs implantation are evident. No structural changes of the spinal cord and brain or signs of abnormal cell proliferation were detected both in the short and long term (Fig. 2) Three patients had MRI at 4 years. No abnormalities of SEPs were detected.

#### 4.4. Clinical follow-up of patients

The follow-up is going on 4 years after the end of the study. Four patients lost to the visits respectively 6, 15, 18 and 30 months after the surgery because the difficulties to attend the monitoring centre. These patients were contacted by telephone. Three patients died for the progression of the disease due to respiratory complications respectively 9, 24 and 44 months after MSCs transplantation. One patient underwent tracheostomy for respiratory complications due to ab ingestis pneumonia 24 months after MSCs implantation and died 16 months later

for infective pulmonary disease. Four patients showed a trend toward a transient slowing down of the decline of the FVC (Fig. 3) and of the functional rating scale scores. One patient shows a progression of the disease with worsening of FVC and functional rating scales but she did not manifest any sign of respiratory failure and polysomnography maintaining normal 51 months after transplantation. No apparent correlations were found between survival and clinical characteristics of patients at the time of recruitment (Table 1). All patients showed a good psychological acceptance of the experimental procedures and manifest their satisfaction for the participation to the study. Four patients think that the treatment was effective and consider the possibility of a new transplant.

#### 4.5. Conclusions

Extensive *in vitro* expansion of MSCs does not involve any functional modification of the cells in ALS patients, including chromosomal alterations or cellular senescence. Hence, there is a good chance that MSCs might be used as a cell-based therapy for ALS patients. Intraparenchymal implantation into the spinal cord of ALS patients with a surgical procedure is requested by the integrity of BBB in

Table 1  
Clinical characteristics of patients at the time of recruitment in the study

Patient	Age	Sex	ALS-FRS score	Norris score	FVC (%)	Bulbar score	Months from diagnosis	Number of cells ( $\times 10^6$ )	Months from implantation to death (†) or to the last contact
1	75	F	25	70	85	7	36	7	24†
2	64	M	34	75	100	7	31	24	48
3	46	F	33	75	108	7	12	30	51
4	32	M	22	44	81	6	81	40	51
5	48	F	30	65	82	7	21	60	9†
6	34	M	13	28	25	3	60	150	44†
7	23	F	16	39	50	7	48	152	54
8	39	M	32	67	100	6	8	24	40†
9	45	F	26	62	53	7	14	32	48

these patients. The results of the long term follow-up (more than 4 years) confirm that intraspinal injection of MSCs in ALS patients is safe as previously reported [40–42]. No signs of toxicity or abnormal growth of the cells were detected both in the short and in the long term. A possible local benefit might be detected in some patients. No patient manifest negative reactions on the psychological well-being. Given the short number of patients and the great variability of the disease however no definite conclusion is possible. A new phase I study is carried out to verify these data in a larger number of patients.

### Acknowledgements

This work was partially supported by Compagnia di San Paolo, Turin; MIUR ex-60% (grant to EM); by the “Fondazione Vialli e Mauro per la Ricerca e lo Sport” and by the Italian Amyotrophic Lateral Sclerosis Association.

### References

- [1] Rowland LP, Shneider NA. Amyotrophic lateral sclerosis. *N Engl J Med* 2001;344:1688–700.
- [2] Boillé S, Yamanaka K, Lobsiger C, et al. Onset and progression in inherited ALS determined by motor neurons and microglia. *Science* 2006;312:1389–92.
- [3] Borchelt DR. Amyotrophic Lateral Sclerosis—are microglia killing motor neurons? *N Engl J Med* 2006;12:1611–3.
- [4] Clement AM, Nguyen EA, Roberts ML, et al. Wild-type nonneuronal cells extend survival of SOD1 mutant motor neurons in ALS mice. *Science* 2003;113–7.
- [5] Corti S, Locatelli F, Donadoni C. Wild-type bone marrow cells ameliorate the phenotype of SOD1-G93A ALS mice and contribute to CNS, heart and skeletal muscle tissues. *Brain* 2004;127:2518–32.
- [6] Nayak MS, Kim YS, Goldman M, Keirstead HS, Kerr DA. Cellular therapies in motor neuron diseases. *Biochim Biophys Acta* 2006;1762:1128–38.
- [7] Klein SM, Behrstock S, McHugh J, et al. GDNF delivery using human neural progenitor cells in a rat model of ALS. *Hum Gene Ther* 2005;16(4):509–21.
- [8] Chi L, Ke Y, Luo C, et al. Motor Neuron Degeneration Promotes Neural Progenitor Cell Proliferation, Migration and Neurogenesis in the Spinal Cords of ALS Mice. *Stem Cells* 2005;24:34–43.
- [9] Pittenger MF, Mackay AM, Beck SC, et al. Multilineage potential of adult human mesenchymal stem cells. *Science* 1999;284:143–7.
- [10] Koc ON, Lazarus IIM. Mesenchymal stem cells: heading into the clinic. *Bone Marrow Transplant* 2001;27:235–9.
- [11] Kim BJ, Seo JH, Bubien JK, Oh YS. Differentiation of adult bone marrow stem cells into neuroprogenitor cells in vitro. *Neuroreport* 2002;13:1185–8.
- [12] Woodbury D, Reynolds K, Black IB. Adult bone marrow stromal stem cells express germline, ectodermal, endodermal, and mesodermal genes prior to neurogenesis. *J Neurosci Res* 2002;69:908–17.
- [13] Jiang Y, Jahagirdar BN, Reinhardt RL, et al. Pluripotency of mesenchymal stem cells derived from adult marrow. *Nature* 2002;418:41–9.
- [14] Lu P, Blesh A, Tuszynski MH. Induction of bone marrow stromal cells to neurons: differentiation, transdifferentiation, or artefact? *J Neurosci Res* 2004;77:174–91.
- [15] Krabbe C, Zimmer J, Meyer M. Neural transdifferentiation of mesenchymal stem cells—a critical review. *APMIS* 2005;113:831–44.
- [16] Mareski K, Novara M, Rustichelli D. Neural differentiation of human mesenchymal stem cells: evidence for expression of neural markers and eag K<sup>+</sup> channel types. *Exp Hematol* 2006;34(11):1563–72.
- [17] Li Y, Chen J, Wang L. Intracerebral transplantation of bone marrow stromal cells in a 1-methyl-4-phenyl-1,2,3,6-tetrahydropyridine mouse model of Parkinson's disease. *Neurosci Lett* 2001;316:67–70.
- [18] Akiyama Y, Radtke C, Honmou O, et al. Remyelination of the spinal cord following intravenous delivery of bone marrow cells. *Glia* 2002;39:229–36.
- [19] Crigler L, Robey RC, Asawachaicharn A, Gaupp D, Phinney DG. Human mesenchymal stem cell subpopulations express a variety of neuro-regulatory molecules and promote neuronal cell survival and neurogenesis. *Exp Neurol* 2006;198:54–64.
- [20] Chopp M, Li Y. Treatment of neural injury with marrow stromal cells. *Lancet Neurol* 2002;1:92–100.
- [21] Terada N, Hamazaki T, Oka M, et al. Bone marrow cells adopt the phenotype of other cells by spontaneous cell fusion. *Nature* 2002;416:542–5.
- [22] Vercelli A, Garbarossa D, Mereuta M, et al. Transplantation of human mesenchymal stem cells into the lumbar spinal cord of G93A mice. *Forum European Neuroscience Vienna*; 2006.
- [23] Bae YS, Furuya S, Shinoda Y. Neurodegeneration augments the ability of bone marrow derived mesenchymal stem cells to fuse with Purkinje neurons in Niemann-Pick Type C mice”. *Hum Gene Ther* 2005;16:1006–11.
- [24] Brooks BR, Miller RG, Swash M, Munsat TL. World Federation of Neurology Research Group on Motor Neuron Diseases. El Escorial revised criteria for the diagnosis of amyotrophic lateral sclerosis. *Amyotroph Lateral Scler Other Motor Neuron Disord* 2000;1:293–9.
- [25] Butcher JN, Dahlstrom WG, Graham JR, Tellegen A, Kaemmer B. MMPI–2: Minnesota Multiphasic Personality Inventory: Manual of Administration and Scoring. Minneapolis: University of Minnesota Press; 1989.
- [26] The ALS-CNTF treatment Study (ACTS) Phase I–II study group. The Amyotrophic Lateral Sclerosis functional rating scale: assessment of activities of daily living in patients with amyotrophic lateral sclerosis. *Arch Neurol* 1996;53:141–7.
- [27] Norris FH, Calanchini PR, Fallat RJ, Panchari S, Jewett B. The administration of guanidine in amyotrophic lateral sclerosis. *Neurology* 1974;24:721–8.
- [28] Brinkmann JR, Andres P, Mendoza M, Sanjak M. Guidelines for the use and performance of quantitative outcome measures in ALS clinical trials. *J Neurol Sci* 1997;147:97–111.
- [29] Magnus T, Beck M, Giess R, Puls I, Naumann M, Toyka N. Disease progression in amyotrophic lateral sclerosis: predictors of survival. *Muscle Nerve* 2002;25:709–14.
- [30] The Italian ALS study group. Branched-chain aminoacids and ALS: a treatment failure? *Neurology* 1993;43:2466–70.
- [31] Kaufmann P, Levy G, Montes J, Buchsbaum R, Barsdorf AI, Battista V, et al. Excellent inter-rater, intra-rater, and telephone-administered reliability of the ALSFRS-R in a multicenter clinical trial. *Amyotroph Lateral Scler Other Motor Neuron Disord* Feb 2007;8(1):42–6.
- [32] McNair DM, Lorr M, Droppleman LF. Profile of Mood State Manual. San Diego: Educational and Industrial Testing Service; 1992.
- [33] Moons P, Marquet K, Budts W, De Geest S. Validity, reliability and responsiveness of the Evaluation of Individual Quality of Life – Direct (SEIQoL-DW) in congenital heart disease. *Health Qual Life Outcomes* 2004;2:27.
- [34] Bacigalupo A, Tong J, Podesta M, et al. Bone marrow harvest for marrow transplantation: effect of multiple small (2 ml) or large (20 ml) aspirates. *Bone Marrow Transplant* 1992;9:467–70.
- [35] Mareschi K, Biasin E, Piacibello W, Aglietta M, Madon E, Fagioli F. Isolation of human mesenchymal stem cells: bone marrow versus umbilical cord blood. *Haematologica* 2001;86:1099–100.
- [36] Stenderup K, Justesen J, Clausen C, Kassem M. Aging is associated with decreased maximal life span and accelerated senescence of bone marrow stromal cells. *Bone* 2003;33:919–26.

- [37] Mareschi K, Ferrero I, Rustichelli D, et al. Expansion of mesenchymal stem cells isolated from pediatric and adult donor bone marrow. *J Cell Biochem* 2006;97:744–54.
- [38] Dominici M, Le Blanc K, Mueller I, Slaper-Cortenbach I, Marini F, Krause D, et al. Minimal criteria for defining multipotent mesenchymal stromal cells. *Cytotherapy* 2006;8(4):315–7.
- [39] Ferrero I, Mazzini L, Rustichelli D, Gunetti M, Mareschi K, Testa L, et al. Mesenchymal stem cells from healthy donors and sporadic ALS patients. EHA Scientific Workshop on Biology and Clinical Applications of Mesenchymal Stem Cells, 2006 October 6–8 Cannes, France; 2006.
- [40] Mazzini L, Fagioli F, Boccaletti R, et al. Stem cell therapy in amyotrophic lateral sclerosis: a methodological approach in humans. *Amyotroph Lateral Scler Other Motor Neuron Disord* 2003;4:158–61.
- [41] Mazzini L, Fagioli F, Boccaletti R. Stem-cell therapy in amyotrophic lateral sclerosis. *Lancet* 2004;364:1936–7.
- [42] Mazzini L, Mareschi K, Ferrero I, et al. Autologous mesenchymal stem cells: clinical applications in amyotrophic lateral sclerosis. *Neurol Res* 2006;28:523–6.